


It's about your journey - PACT MATTERS (www.pactmatters.com)


OPHTHALMIC IMAGING: Lights, Camera, & Magnification

M. Parker, PhD, DSc., CLSSMBB, PMP, CTC, COMT,
(F)ATPO



Ohio Ophthalmological Society 2024

1



It's about your journey - PACT MATTERS (www.pactmatters.com)

DISCLOSURES

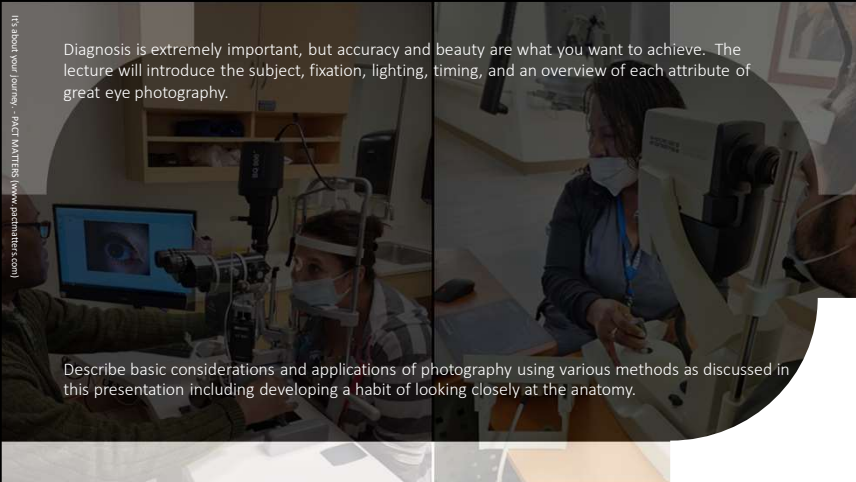
M. Parker, PhD, DSc., CLSSMBB, PMP, CTC, COMT,
(F)ATPO

CEO & Principal Consultant for LEAN Ophthalmology
Training and Certification
PACT MATTERS, LLC

Government Consultant for Practice Management,
Process Improvement & Ophthalmic Training

Ohio Ophthalmological Society 2024

2

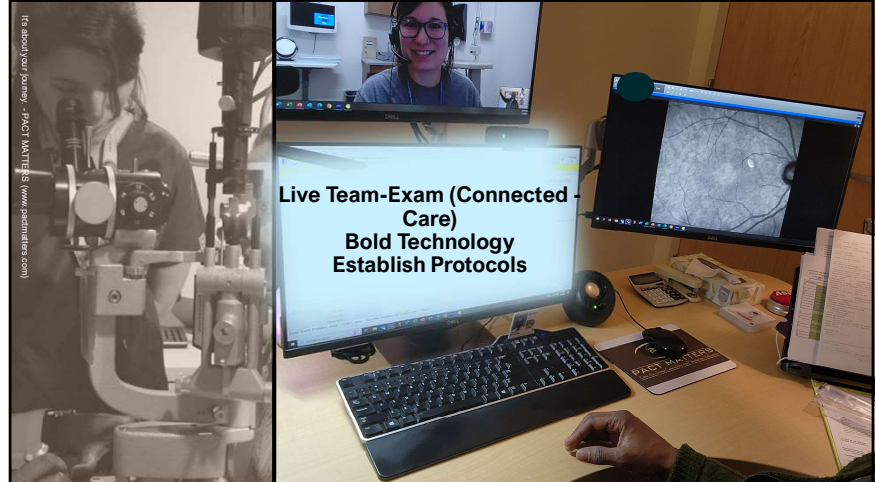


It's about your journey - PACT MATTERS (www.pactmatters.com)

Diagnosis is extremely important, but accuracy and beauty are what you want to achieve. The lecture will introduce the subject, fixation, lighting, timing, and an overview of each attribute of great eye photography.

Describe basic considerations and applications of photography using various methods as discussed in this presentation including developing a habit of looking closely at the anatomy.

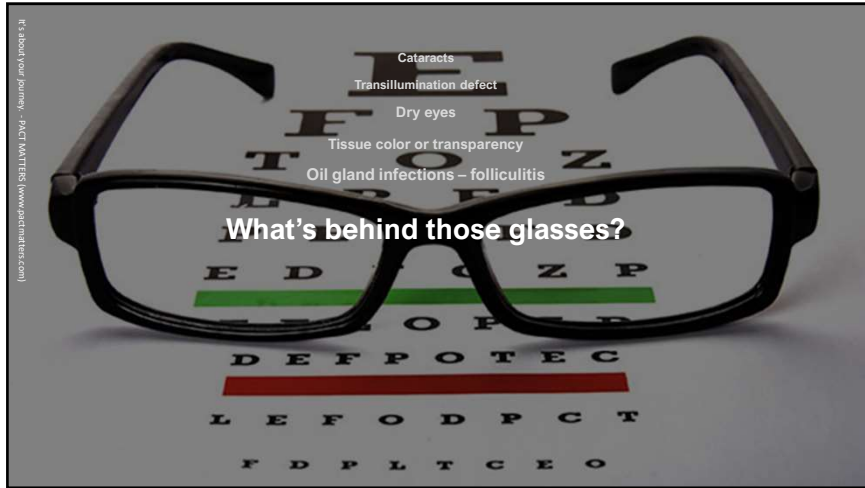
3



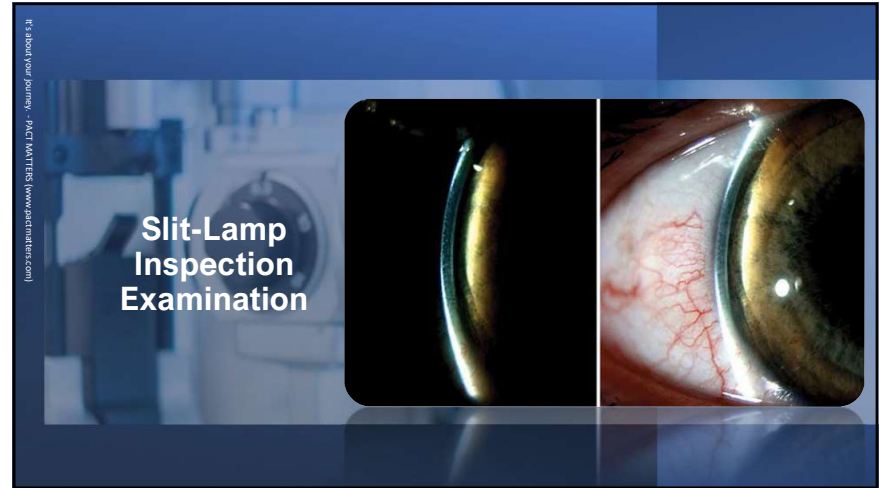It's about your journey - PACT MATTERS (www.pactmatters.com)

Live Team-Exam (Connected Care)
Bold Technology
Establish Protocols

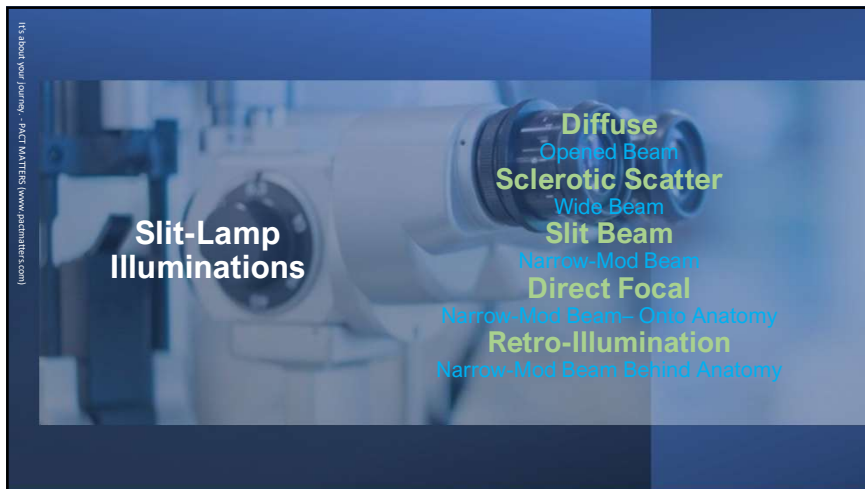
4



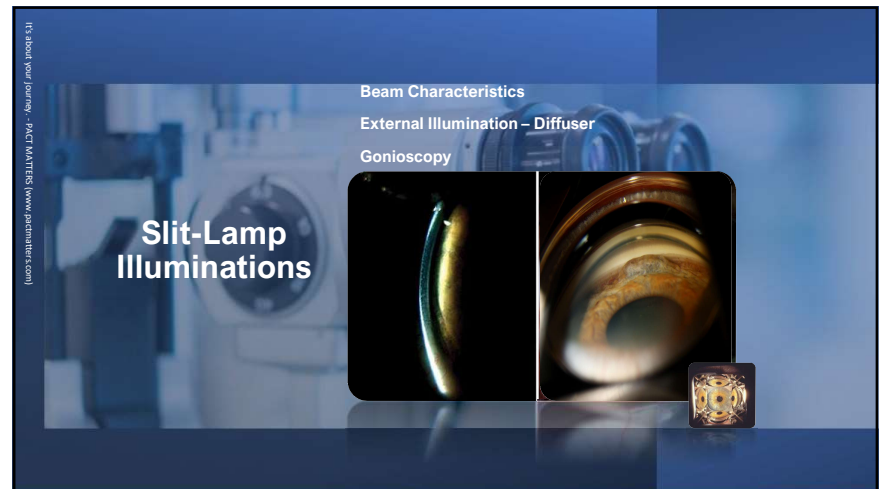
5



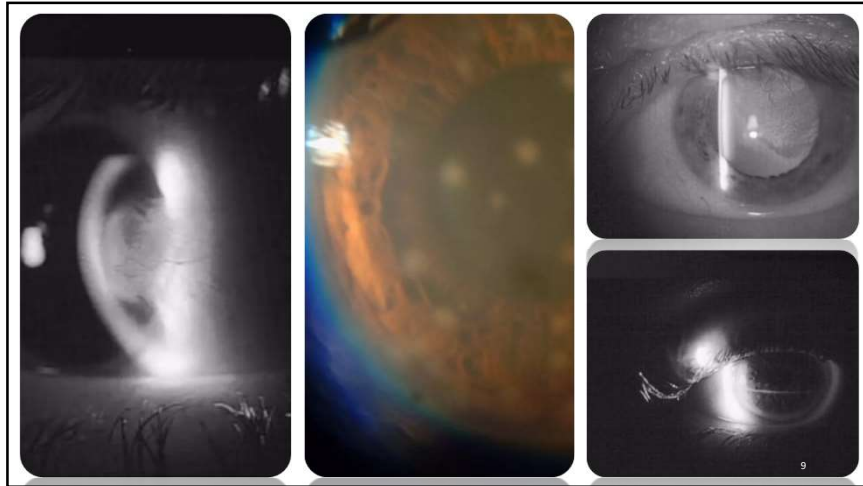
6



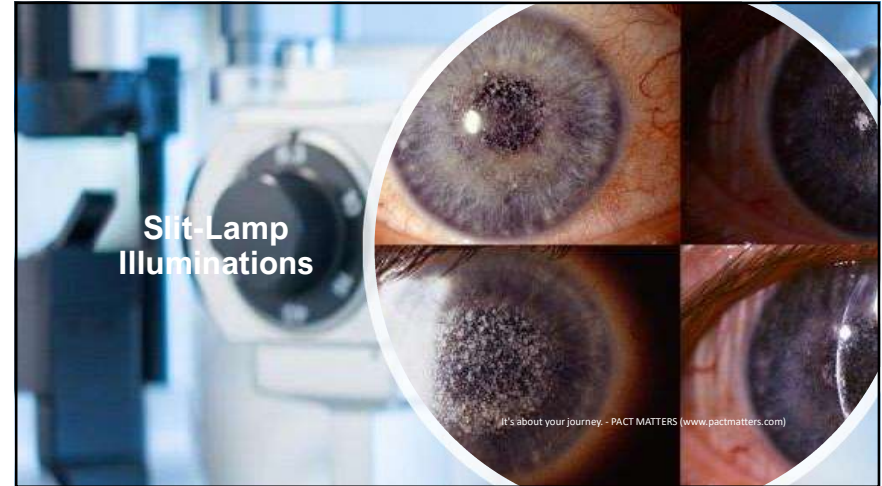
7



8



9



10

It's about your journey - PACT MATTERS (www.pactmatters.com)

Comprehensive Slit-Lamp Examination

- Lids, Lashes, Lacrimal (L/L/L)
- Conjunctiva, Sclera (C/S)
- Cornea (K)
- Anterior Chamber (A/C)
- Iris (I)
- Lens (L)
- Anterior Vitreous (A/V)

11

It's about your journey - PACT MATTERS (www.pactmatters.com)

Comprehensive Slit-Lamp Examination

- (L/L/L) – lagging, ex/entropion, blepharitis, trauma
- (C/S) – vascularity, lesions
- (K) – ulcers, abrasions, thickening
- (A/C) – depth, cells, flares, fb
- (I) – transillumination defects, rubeosis, pupil
- (L) – cataracts, IOL
- (A/V) - hemorrhages

12

It's about your journey - PACT MATTERS (www.pactmatters.com)

Comprehensive Slit-Lamp Examination

Process – routine – repetition – results
 Lights (illumination management)
 Focal beam variable height, width and angle
 Location (relativity, nasal, temporal)
 Magnification (Best and detailed views)
 Process – routine – repetition - results

- A. Use of lights
- B. Anatomy
- C. Magnifications




13

It's about your journey - PACT MATTERS (www.pactmatters.com)

- A. Use of lights
- B. Anatomy
- C. Magnifications

General Presentation

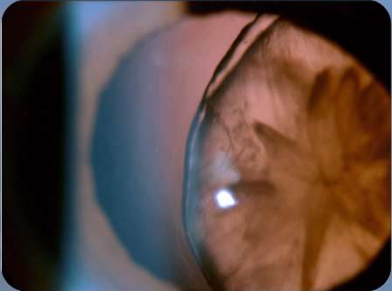


14

It's about your journey - PACT MATTERS (www.pactmatters.com)

- A. Use of lights
- B. Anatomy
- C. Magnifications

General Presentation

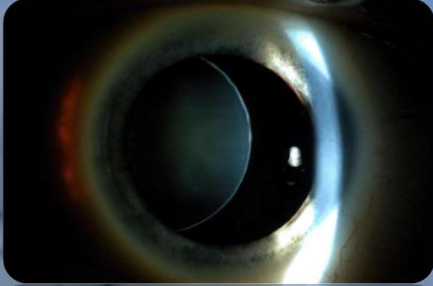


15

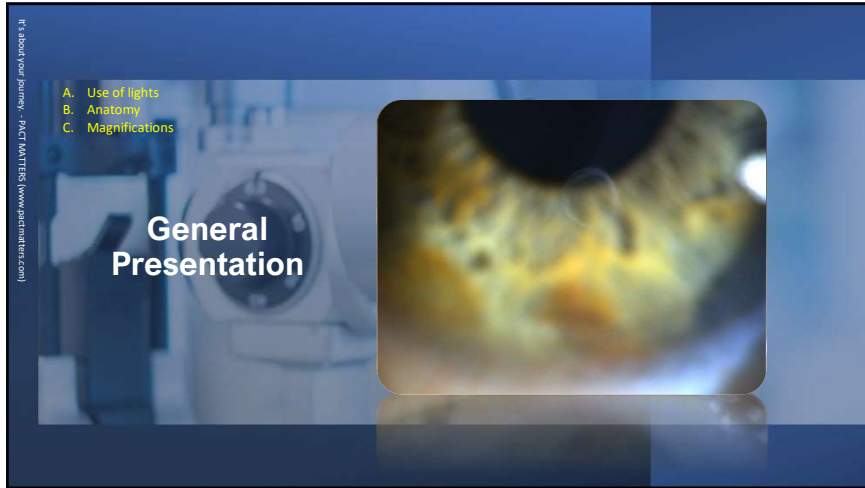
It's about your journey - PACT MATTERS (www.pactmatters.com)

- A. Use of lights
- B. Anatomy
- C. Magnifications

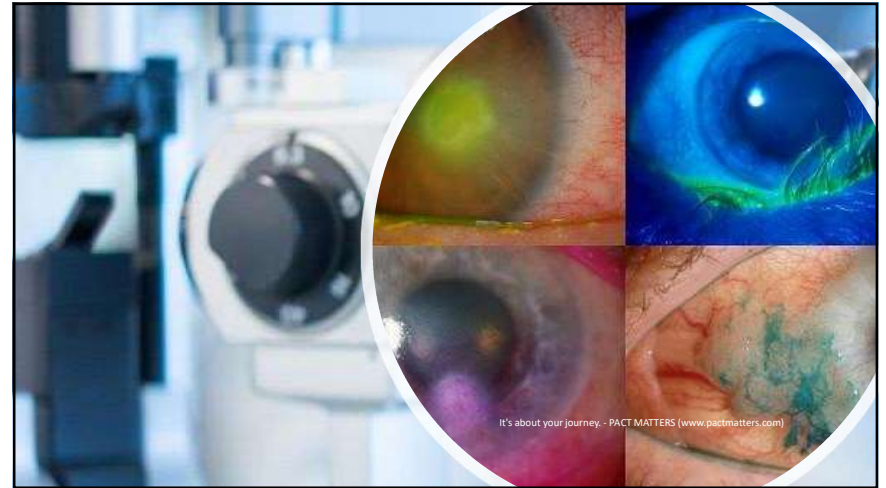
General Presentation



16



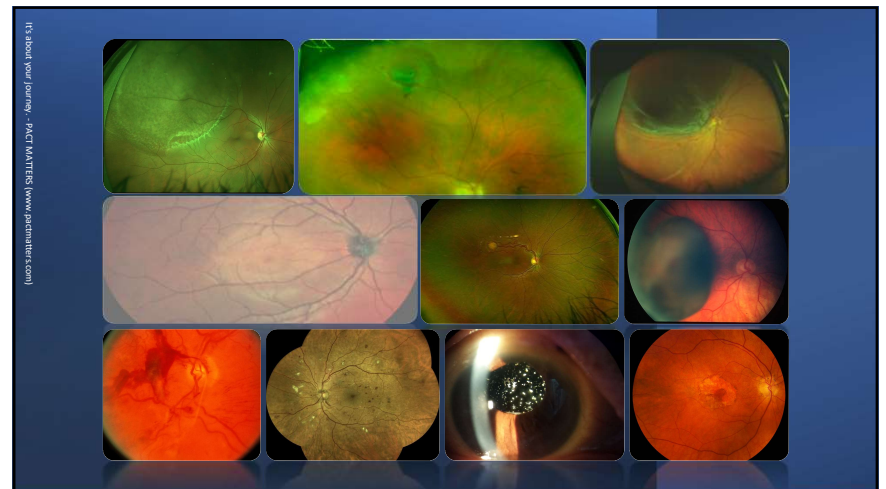
17



18



19



20

It's about your journey - PACT MATTERS (www.pactmatters.com)

- A. Use of lights
- B. Anatomy
- C. Magnifications

Retinal Detachment



Courtesy by Loma Linda University - Ophthalmology Residency Program
Department of Veterans Affairs Loma Linda Healthcare System, Surgical - Ophthalmology

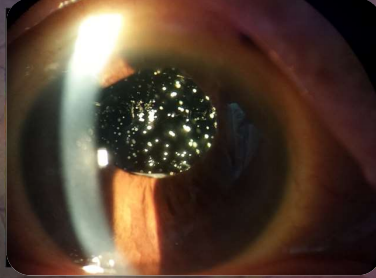
This fundus photograph shows a retinal detachment. The detached retina is visible as a pale, elevated area on the left side of the image, with a distinct line separating it from the attached retina. The optic disc is visible on the right.

21

It's about your journey - PACT MATTERS (www.pactmatters.com)

- A. Use of lights
- B. Anatomy
- C. Magnifications

Asteroid Hyalosis



Courtesy by Loma Linda University - Ophthalmology Residency Program
Department of Veterans Affairs Loma Linda Healthcare System, Surgical - Ophthalmology

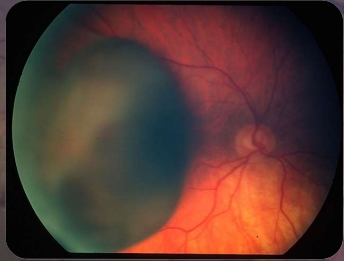
This fundus photograph shows asteroid hyalosis, characterized by numerous small, white, cholesterol crystals (asteroids) that are suspended in the vitreous body. The crystals appear as bright, refractile spots that partially obscure the underlying retinal structures.

22

It's about your journey - PACT MATTERS (www.pactmatters.com)

- A. Use of lights
- B. Anatomy
- C. Magnifications

Choroidal Melanoma



Courtesy by Loma Linda University - Ophthalmology Residency Program
Department of Veterans Affairs Loma Linda Healthcare System, Surgical - Ophthalmology

This fundus photograph shows a choroidal melanoma. The tumor appears as a dark, pigmented, dome-shaped mass on the choroid, with a distinct shadow cast on the underlying retina. The optic disc is visible on the right.

23

It's about your journey - PACT MATTERS (www.pactmatters.com)

- A. Use of lights
- B. Anatomy
- C. Magnifications

Cotton Wool Spots



Courtesy by Loma Linda University - Ophthalmology Residency Program
Department of Veterans Affairs Loma Linda Healthcare System, Surgical - Ophthalmology


This fundus photograph shows cotton wool spots, which are pale, fluffy patches of retinal nerve fiber layer infarction. They are located in the peripapillary region and are characterized by their soft, cotton-like appearance. The optic disc is visible on the right.

24

It's about your journey - PACT MATTERS (www.pactmatters.com)

- A. Use of lights
- B. Anatomy
- C. Magnifications

Floaters



Courtesy by Loma Linda University - Ophthalmology Residency Program
Department of Veterans Affairs Loma Linda Healthcare System, Surgical - Ophthalmology

25

It's about your journey - PACT MATTERS (www.pactmatters.com)

- A. Use of lights
- B. Anatomy
- C. Magnifications

Hemangioma



Courtesy by Loma Linda University - Ophthalmology Residency Program
Department of Veterans Affairs Loma Linda Healthcare System, Surgical - Ophthalmology

26

It's about your journey - PACT MATTERS (www.pactmatters.com)

- A. Use of lights
- B. Anatomy
- C. Magnifications

Horseshoe Tear



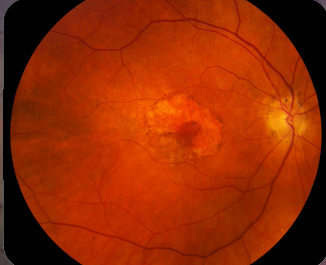
Courtesy by Loma Linda University - Ophthalmology Residency Program
Department of Veterans Affairs Loma Linda Healthcare System, Surgical - Ophthalmology

27

It's about your journey - PACT MATTERS (www.pactmatters.com)

- A. Use of lights
- B. Anatomy
- C. Magnifications

Macular Degeneration



Courtesy by Loma Linda University - Ophthalmology Residency Program
Department of Veterans Affairs Loma Linda Healthcare System, Surgical - Ophthalmology

28

It's about your journey - PACT MATTERS (www.pactmatters.com)

- A. Use of lights
- B. Anatomy
- C. Magnifications

Retinal Detachment

Retinoschisis



Courtesy by Loma Linda University - Ophthalmology Residency Program
Department of Veterans Affairs Loma Linda Healthcare System, Surgical - Ophthalmology

29

It's about your journey - PACT MATTERS (www.pactmatters.com)

- A. Use of lights
- B. Anatomy
- C. Magnifications

Vitreous Hemorrhage



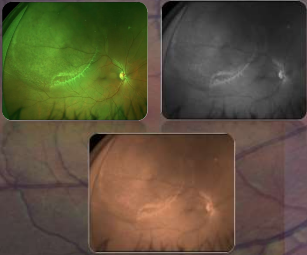
Courtesy by Loma Linda University - Ophthalmology Residency Program
Department of Veterans Affairs Loma Linda Healthcare System, Surgical - Ophthalmology

30

It's about your journey - PACT MATTERS (www.pactmatters.com)

- A. Use of lights
- B. Familiar with instrument
- C. Various magnifications

Filters



Courtesy by Loma Linda University - Ophthalmology Residency Program
Department of Veterans Affairs Loma Linda Healthcare System, Surgical - Ophthalmology

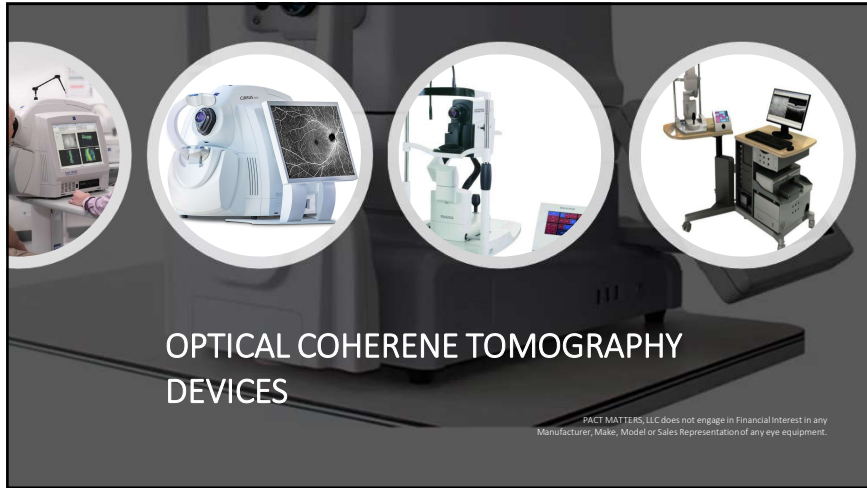
31

It's about your journey - PACT MATTERS (www.pactmatters.com)

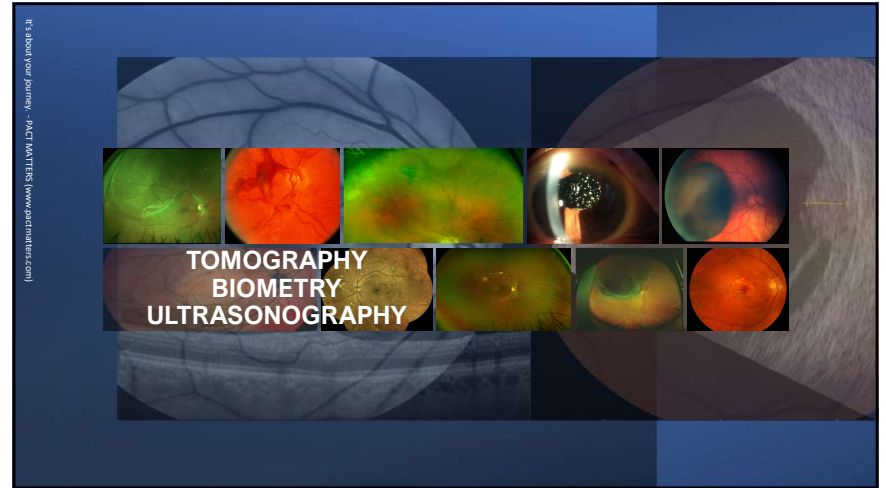


Courtesy by Loma Linda University - Ophthalmology Residency Program
Department of Veterans Affairs Loma Linda Healthcare System, Surgical - Ophthalmology

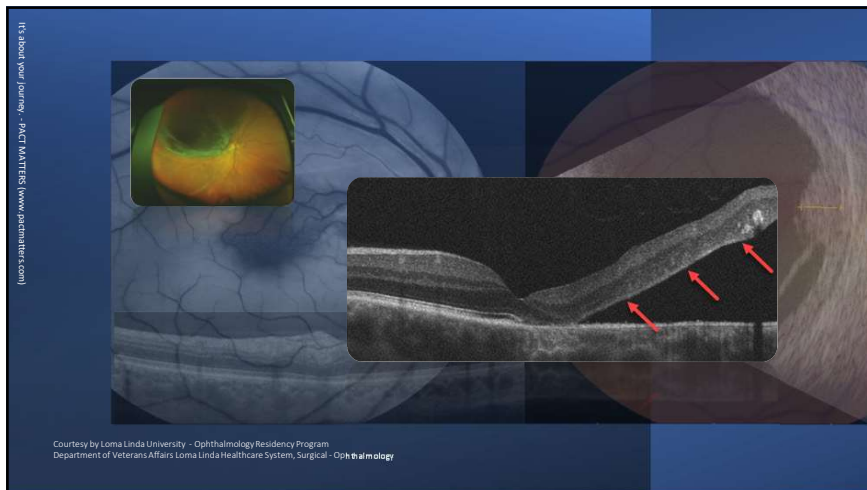
32



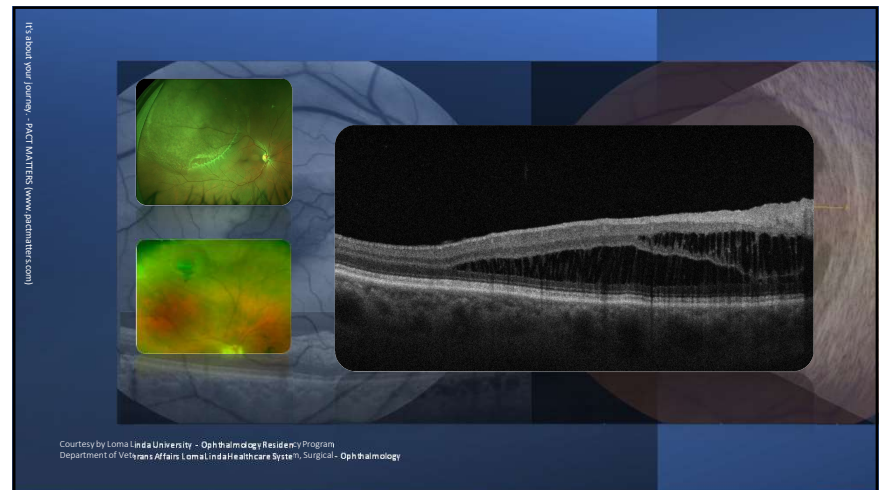
33



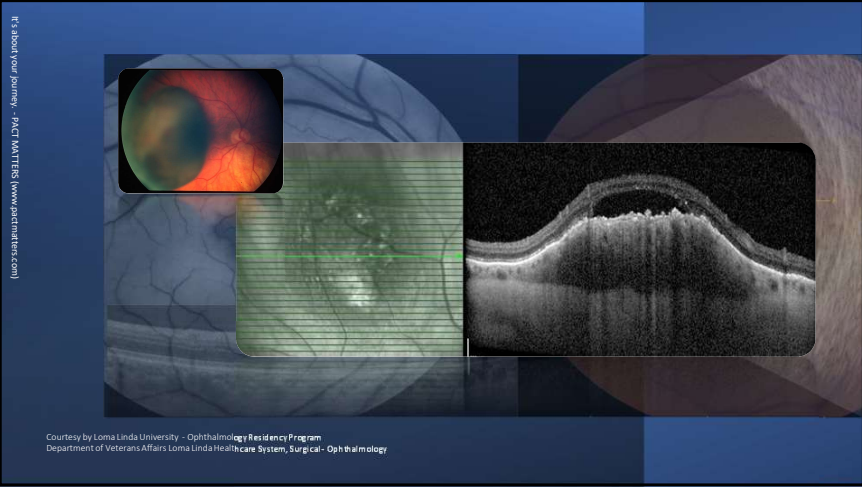
34



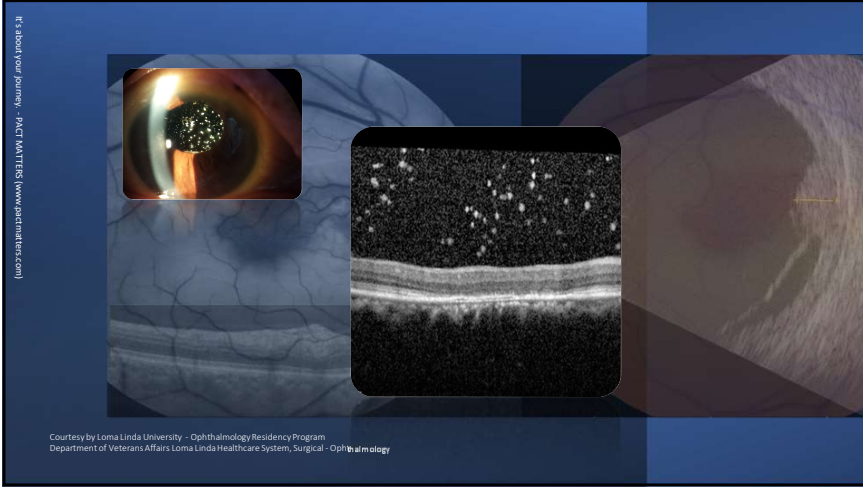
35



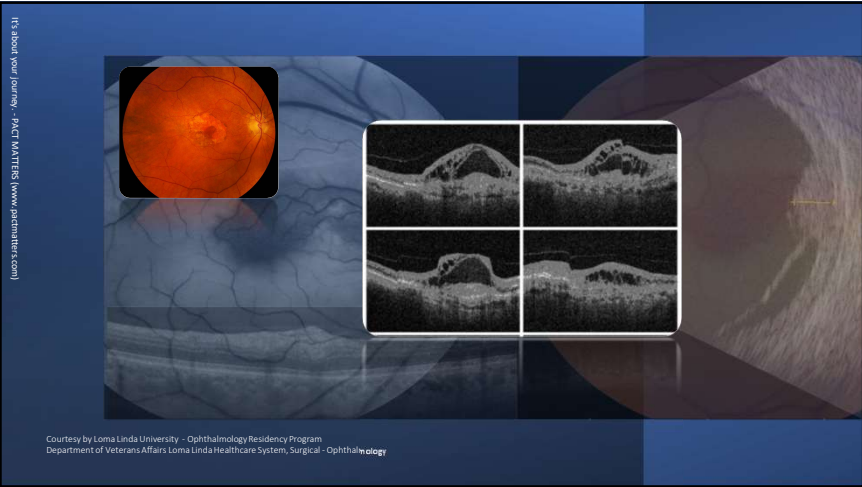36



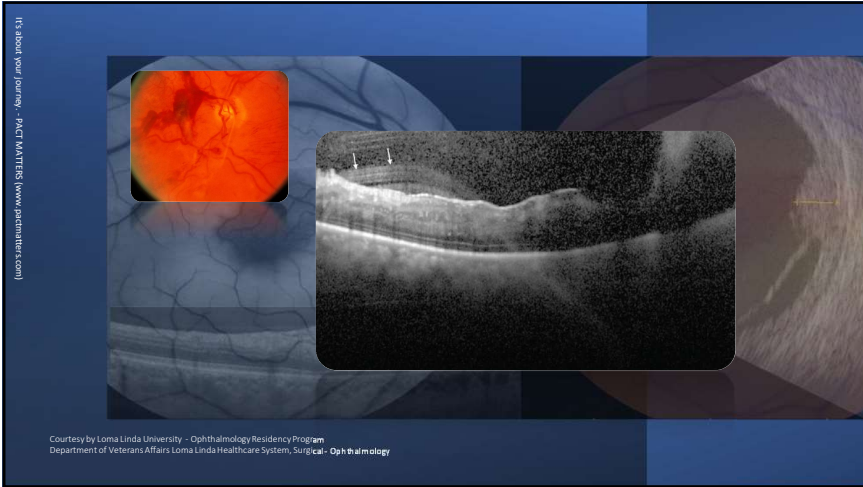37



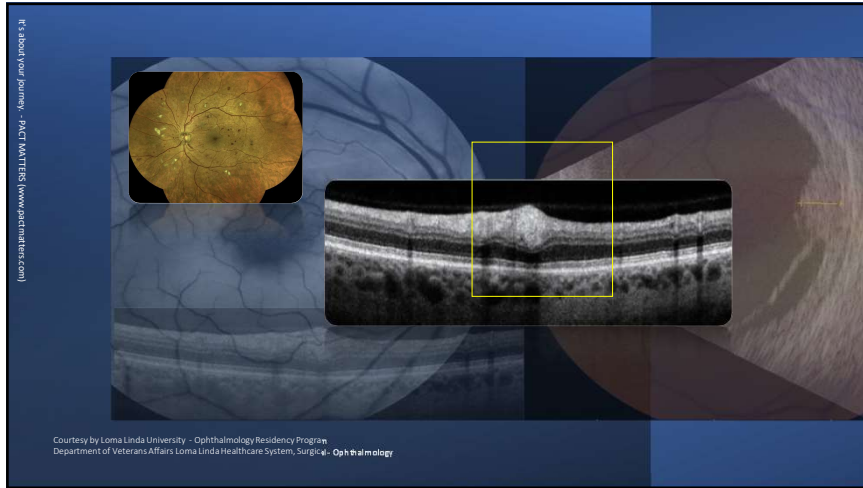
38



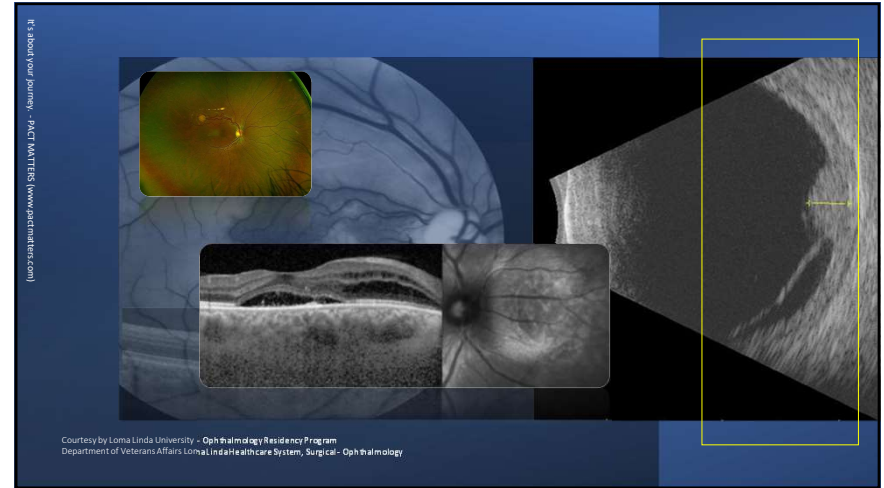
39



40



41



42

Impact of Timely Diagnosis

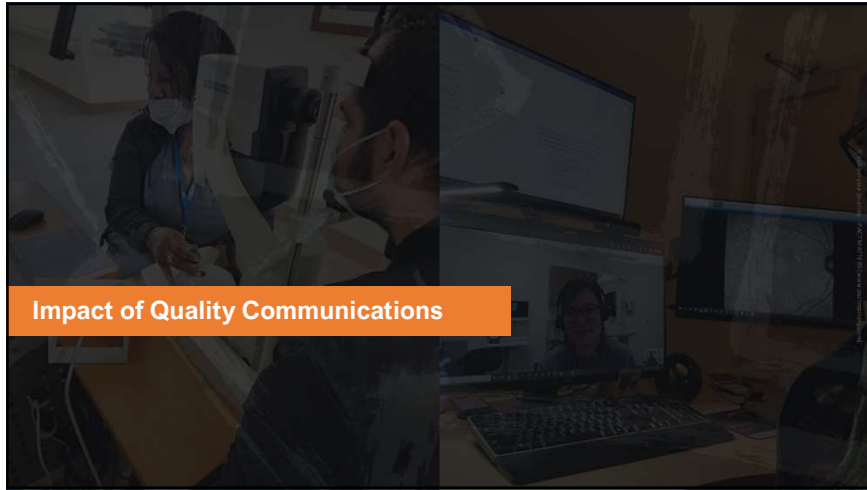
<p>Use of lights Familiar with instrument Various magnifications</p>	<p>Live Team-Exam (Connected Care) Bold Technology Establish Protocols</p>
---	---

43

Impact of Photo Mechanics - References

<p>Use of lights Familiar with instrument Various magnifications</p>	<p>Live Team-Exam (Connected Care) Bold Technology Establish Protocols</p>
---	---

44



Impact of Quality Communications

45

AMERICAN ACADEMY OF OPHTHALMOLOGY®
Protecting Sight. Empowering Lives.

American Academy of Ophthalmic Executives (AAOE)

American Academy of Ophthalmic Professionals (AAOP)

page 46

46

It's about your journey... PACT MATTERS! (www.pactmatters.com)

**OPHTHALMIC IMAGING:
Lights, Camera, & Magnification**

M. Parker, PhD, DSc., CLSSMBB, PMP, CTC, COMT
(F)ATPO

Ohio Ophthalmological Society 2024

47